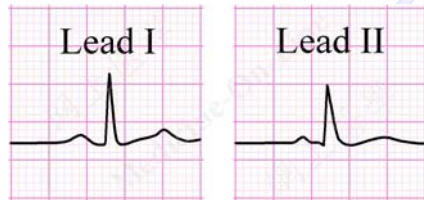
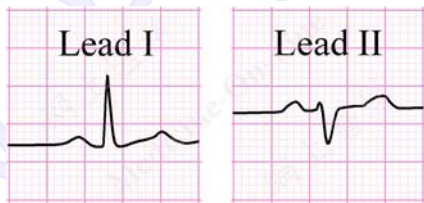


On occasions the QRS complexes in all 6 limb leads are biphasic, neither positive nor negative. In these instances the QRS axis is said to be indeterminate.

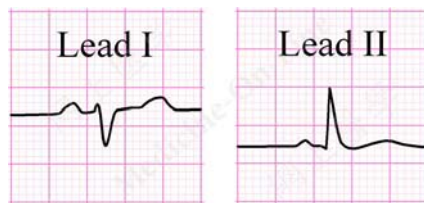
In summary:



Normal QRS axis.



Left axis deviation



Right axis deviation

