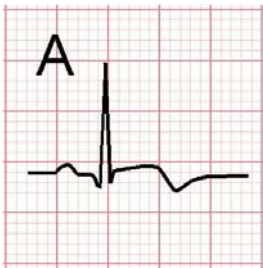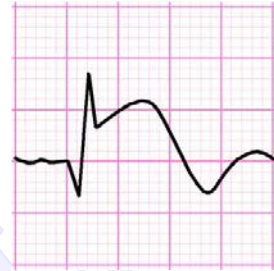




Hyperacute (tall positive) T waves may precede ST segment elevation (A) or seen at the same time with ST elevation (B) during this acute phase.

Hours to days later during the evolving phase, pathological Q waves appear, the elevated ST segments return towards baseline, and the T waves become inverted.



Q wave is normal if it is shallow and brief (A).

Q wave is pathological if it is wider than 40 ms or deeper than a third of the height of the entire QRS complex (B & C). Significant Q wave usually persists even after recovery.

